

Verminous pneumonia in a calf from a dairy farm unit

Vahedi Noori N^{1*} and Salehi A²¹Veterinary Group, Animal Science Research Department, Mazandaran Agricultural and Natural Resources Research and Education Center, AREEO, Sari, Iran²Veterinary Medicine, Babol Islamic Azad University, Iran

Abstract

Following a report of a respiratory problem in a calf's head with an approximate age of 60 days, a livestock unit has undergone basic examinations. Symptoms such as coughing, Epistaxis and fever of 40° C, based on symptomatic treatment and due to relatively high temperatures, have been prescribed antibiotics along with serum, but over time, in the process of improving the progression of the livestock, the calf has been wasted. With an autopsy and the lung examination, a huge amount of white and thick mucosal secretions as well as a number of parasite larvae have also been isolated within the bronchi. The morphological characteristics of these larvae have been confirmed by *Dictyocaulus viviparus* parasite infection. Basically, the role of parasitic agents in the development of pneumonia in calves is very significant. Due to the lesser consideration of the role of parasitic agents in the calf's pneumonia and in addition to the high cost of treatment, this, ultimately leads to the death of calves. Therefore, in dealing with such cases, Paraclinical tests such as stool test is also suggested.

Introduction

Respiratory diseases after diarrhea are the second most problematic for the health of young calves in the livestock industry [1]. Most respiratory diseases occur in calves at the age of six to eight weeks. Their occurrence is usually accompanied by the interference of one or more infectious agents with stressful and favorable factors such as transportation, ventilation and inappropriate nutrition. One of the important factors in the development of respiratory diseases, especially in calves, is parasitic agents [2]. Of the common pulmonary parasites, the role of two nematodes *Dictyocaulus viviparus* and *Dictyocaulus filaria* is remarkable. Unlike other parasites, these parasites have a direct evolution and are easily transmitted. Larvae of These parasites are the only infants that are seen in fresh cattle feces, so they can be easily diagnosed with simple stool testing. The larvae can be transferred to the outside of the skin and then transferred to the third stage larvae, then scraped out of the stool by motility or by spores of the *Pilobolus* mushroom and eaten by the animal and causing contamination [3]. This article studies the occurrence of pneumonia in a calf head from a semi-industrial livestock unit in Mazandaran province.

Clinical report

Following a report of a respiratory problem in a calf's head at an approximate age of 60 days, in a semi-industrial livestock unit in Mazandaran province, the calf has undergone a first-time clinical examination. The examination showed that the calf had symptoms such as: coughing, respiratory movements, Nasal discharge, salivation, anorexia and fever (40° C). Because of relatively high temperature and based on symptomatic treatment and the initial diagnosis of respiratory infection of bacterial origin, administration of antibiotics including gentamicin and lincospectin, along with serum therapy and multivitamin injection for 5 days, has been started on the animal, but it was not helpful, and the calf wasted. In addition to observing a large amount of white and concentrated mucosal secretions inside the bronchus, several larvae of the parasite have also been isolated by performing a calf test and initial examination of the lung. The

morphological characteristics of these larvae have confirmed the *Dictyocaulus viviparus* parasitic infection.

Discussion

Among the factors that cause pneumonia in the calves, parasitic agents, and especially the *Dictyocaulus viviparus*, are significant both in cattle and in calves [1]. This parasite has a direct evolution, although in most cases, in the weeks and months after the infection, we can see a gradual improvement of the affected areas, but in the calves at the pre-exposure stage, at severe-infested livestock, dyspnea develops suddenly and the animal is wasted 48-24 hours later (Figure 1). Because of many reasons, the attention of most veterinary clinicians when dealing with pneumonia, especially in calves, is often focused on bacterial or viral infections, and less attention is paid to the role and importance of the infection of pulmonary parasites in this area, so recognizing the pattern of the types of pneumonia and its productive factors, as well as the need for Paraclinical tests, such as stool test and their correct interpretation, are very important in their treatment and control [4]. Given that calf prevention treatment with anti-worm medicines won't be successful before the emergence of bronchitis-related clinical signs. The only successful way to prevent the formation of bronchitis with clinic addresses is vaccination of calves by eating live *Dictyocaulus viviparus* larvae (Affected by X-rays) (Figure 2), however, if the bronchitis is detected in the calves, it can be stopped for two weeks with two or three anti-worm treatments such as Levamisole, Benzimidazole and Ivermectin [5].

*Correspondence to: Vahedi Noori N, Veterinary Group, Animal Science Research Department, Mazandaran Agricultural and Natural Resources Research and Education Center, AREEO, Sari, Iran, E-mail: nsvahedi@yahoo.com

Key words: verminous pneumonia, calf, farm

Received: March 06, 2019; **Accepted:** March 13, 2019; **Published:** March 15, 2019



Figure 1. Sick calf

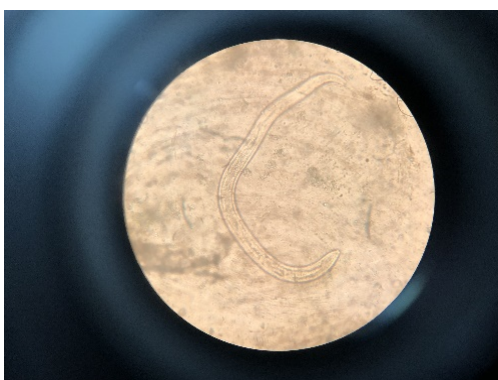


Figure 2. Dictyocaulus viviparus larvae

References

1. Blood DC, Radotitis OM, Henderson JA (1983) Veterinary medicine, 9th Ed. London: Bailliere Tindall.
2. Soulsby EJJ (1982) Helminths Arthropods and Protozoa of Domesticated Animals (7th Ed) Bailliere Tindall. London 294.
3. Moazeni M, Jafti A (2007) Verminous pneumonia in a calf caused by Dictyocaulus filarial. *Vet Rec* 160: 380. [[Crossref](#)]
4. Panciera RJ, Confer AW (2010) Pathogenesis and Pathology of Bovine Pneumonia. *Vet Clin North Am Food Anim Pract* 26: 191-214. [[Crossref](#)]
5. Poynter D (1963) Parasitic Bronchitis. *Adv Parasitol* 1: 179-212. [[Crossref](#)]